Short Communication

Effects of para-toluenesulfonamide intratumoral injection on pulmonary adenoid cystic carcinoma complicating with severe central airway obstruction: a 5-year follow-up study

Wei-Jie Guan, Shi-Yue Li, Nan-Shan Zhong

State Key Laboratory of Respiratory Disease, National Clinical Research Center for Respiratory Disease, Guangzhou Institute of Respiratory Health, The First Affiliated Hospital of Guangzhou Medical University, Guangzhou 510120, China

Correspondence to: Nan-Shan Zhong, MD. State Key Laboratory of Respiratory Disease, National Clinical Research Center for Respiratory Disease, Guangzhou Institute of Respiratory Health, The First Affiliated Hospital of Guangzhou Medical University, 151 Yanjiang Road, Guangzhou 510120, China. Email: nanshan@vip.163.com.

Abstract: Pulmonary adenoid cystic carcinoma (ACC) is a rare type of non-small cell lung carcinoma that may develop life-threatening severe malignant airway obstruction (SMAO). Currently, limited therapeutic approaches exist for ACC-SMAO. We investigated the efficacy and safety of para-toluenesulfonamide (PTS) intratumoral injection for ACC-SMAO. In this phase III, multicenter, non-randomized, single-arm, open-label trial, we recruited eight hospitalized patients with ACC-SMAO between October 2009 and January 2011. Within the first year, patients received PTS injection for 2–3 sessions weekly, with 2 weeks as a single course. Pre- and post-treatment assessments, including vital sign assessment, dyspnea index, chest computed tomography (CT), were performed shortly before PTS injection and at day 30 post-treatment. We extended the observation to 5 years to determine overall survival. The primary endpoint was the CT-assessed airway objective response rate (ORR) at day 30. The key secondary endpoint was the overall survival (OS) at 5 years post-treatment. At baseline, mean airway tumor cross-sectional area was 153.3 mm2 (n=8), and the mean airway obstruction rate was 86.1%. The airway ORR reached 100% (33.3% complete remission and 66.7% partial remission). PTS treatment reduced the airway tumor size from 158.2 to 22.7 mm2 and the average airway obstruction rate decreased from 83.1% to 14.4% (n=6). The 5-year overall survival rate was 50.0%. Median survival duration was 4.98 years (range, 1.39–5.00 years). Four patients (50.0%) had stable disease. Compared with baseline dyspnea index, the transitional dyspnea index increased significantly at 30 days after treatment (mean difference: 5.40, 95% CI, 0.31–10.49; P<0.05). Adverse events were reported in 75% of patients (n=6), of whom 33.3% (n=2) and 66.7% (n=4) were rated as mild and moderate, respectively. No SAE was reported. In conclusion, PTS could rapidly debulk ACC-SMAO, resulting in considerable improvement of five-year survival rate.

Keywords: Para-toluenesulfonamide (PTS); intratumoral injection; cystic adenoid carcinoma; severe airway obstruction; survival

Submitted May 02, 2017. Accepted for publication Feb 26, 2018.
doi: 10.21037/jtd.2018.03.70
View this article at: http://dx.doi.org/10.21037/jtd.2018.03.70

Introduction

Pulmonary adenoid cystic carcinoma (ACC), a rare type of non-small cell lung carcinoma (NSCLC), may develop severe malignant airway obstruction (SMAO) which is frequently life-threatening (1). Overall, the 5-year survival of patients with ACC is ~52% (2). However, surgical resection is limited by the size and location of ACC. The 5-year survival of patients with inoperable ACC is merely 33%. To date, there is no effective therapeutic option for ACC-SMAO, highlighting urgent unmet needs of developing novel therapeutic regimens.

Para-toluenesulfonamide (PTS) is a low-molecular-weight organic compound that confers powerful anti-tumor effects in mouse models by eliciting tumor necrosis whilst resulting in minimal injury to adjacent normal tissues (3). In a multicenter, single-arm, open-label trial (www.chictr.org/cn, No.: ChiCTR-TNC-12002648), PTS intratumoral injection significantly alleviated airway obstruction and improved lung function in patients with NSCLC-SMAO (4). However, therapeutic responses of ACC-SMAO to PTS injection might differ from that of other pathological subtypes of NSCLC. Because the observation spanned for only 1 year, the long-term survival following PTS treatment remains unclear. We hypothesized that PTS intratumoral injection would be equally, if not more, effective for ACC-SMAO. Here, we specifically analyzed the effects of PTS intratumoral injection in patients with ACC-SMAO by extending follow-up to 5 years (5).

Methods

This is a sub-analysis of the patients with ACC who were included in the analysis of our previous paper. Therefore, this study has extended from the previous study by specifically analyzing the survival of patients with surgically inoperable ACC-SMAO (5).

Between October 2009 and January 2011, we prospectively recruited eight hospitalized patients with ACC-SMAO from four medical centers in China. Eligibility criteria included: (I) 18–83 years of age; (II) physician-diagnosed ACC according to tumor biopsy findings and ACC cell morphological classification as described previously (6). SMAO was defined as the ratio of tumor/trachea diameter being 0.50 or greater, the ratio of tumor/main bronchi diameter being 0.67 or greater, or the longest tumor diameter being greater than 0.5 cm (evaluated with bronchoscopy); (III) lesions suitable for bronchoscopic treatment; (IV) tumor sizes measurable with computed tomography (CT); (V) no thrombocytopenia. Key exclusion criteria were cerebral metastasis and severe cardiovascular diseases. Protocol approval was obtained from Ethics Committee of participating sites and China Food and Drug Administration [No.: 2009L03443; Medical Ethics Year 2009 (the 12th) and Medical Ethics Year 2016 (the 33rd) for follow-up study]. Informed consent forms were signed before enrollment.

This was a phase III, multicenter, non-randomized, single-arm, open-label trial. Randomized, double-blind, parallel-group study was not conducted because it was deemed unethical, according to local ethics committee and China Food and Drug Administration. Both physicians and patients were aware of treatment allocation. Pre-clinical toxicity studies have established the initial dose in human to be 3.0 mL/d. A phase I dose-escalation study in human has confirmed that the daily tolerable dose for intratumoral injection of PTS was 10 mL, which was selected as the daily dose in the present study. Each ampoule contained 5 mL of PTS, and up to two ampoules of PTS would be administered to the patients per each treatment day (diluted in ethanol absolute).

The methodology of PTS intratumoral injection has been described previously (5). Before injection, 5 mL PTS (Lot No.: 070109-070111; Guangdong Dari Chemicals Inc., Guangzhou, China) was diluted with 2 mL ethanol anhydride into a 10 mL sterile syringe (ethanol concentration: 28.5%). PTS-ethanol mixture was intratumorally injected to tumor's root. Within the first year, patients with ACC-SMAO received PTS injection for 2–3 sessions weekly, with 2 weeks as a single course. Four doses were mandatory for the initial course, but the doses could be adjusted for the remaining courses. After the 4 doses of PTS administration, no further PTS dosing would be performed when the airway tumor size had been reduced by at least 50%.

Pre- and post-treatment assessments, including vital sign assessment, dyspnea index, chest CT, were performed shortly before PTS injection and at day 30 after treatment. We also extended the observation period to five years to determine overall survival (OS) (*Figure 1*). Adverse events were, if any, documented.

The primary endpoint was the airway objective response rate (ORR), assessed with chest CT at day 30, based on Response Evaluation Criteria In Solid Tumor (RECIST). The CT assessment was used to evaluate the

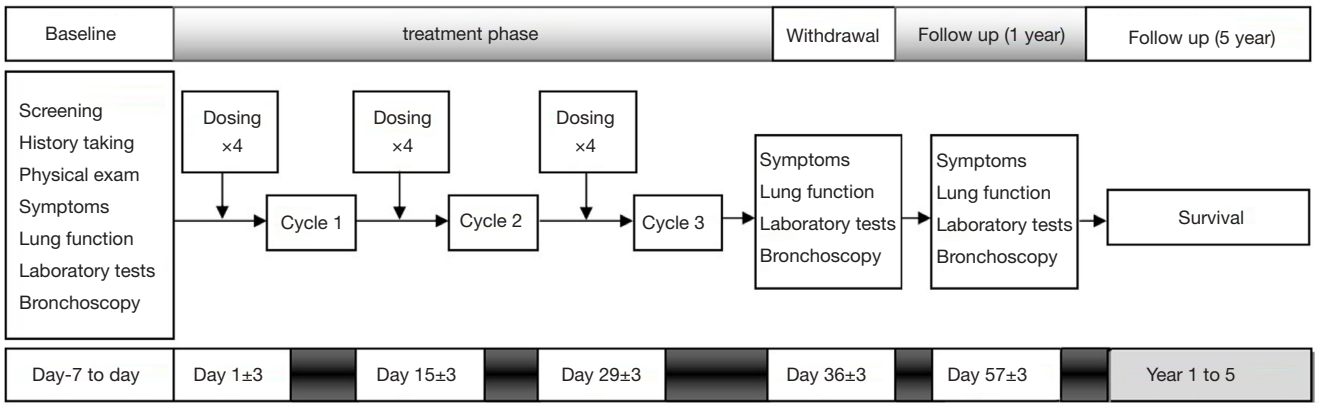

Figure 1 Study flow chart.

airway obstruction rate and the magnitude of alleviation of airway obstruction at day 30 post-treatment. Meanwhile, bronchoscopic assessment of airway tumor area and airway obstruction at day 30 post-treatment was also conducted. K-PACS (IMAGE Information Systems Ltd. London, United Kingdom) and MensurePlus (Guangzhou Institute of Respiratory Health, Guangzhou, China) was used for CT and bronchoscopic image measurement, respectively. Bronchoscopic results, which demonstrated similar trends of changes with chest CT, are listed in *Table S1*. The key secondary endpoint was the OS at 5 years post-treatment. Other secondary endpoints included: (I) Transitional Dyspnea Scale (TDI), measured at day 30 and 1-year post-treatment; (II) forced expiratory volume in one second (FEV_1), measured at day 30 post-treatment; and (III) the ratio of FEV_1 to forced vital capacity (FEV_1/FVC), measured at day 30 post-treatment. Adverse events (AE) and severe adverse events (SAE) were recorded and presented as numbers and percentages.

We analyzed the endpoints based on the modified intention-to-treat principle. Full-analysis set included patients who received at least one dose of PTS (n=8). All patients had received at least 4 injections in this study. All analyses were performed for the full-analysis set. Data were processed with Graphpad Prism 5.0 (Graphpad Inc., USA). Full-analysis set included eight patients who had received PTS treatment. Numeric data were described as mean ± standard deviation, whereas treatment effect was presented as mean difference [95% confidence interval (95% CI)]. Survival was analyzed with log-rank test.

Results

Baseline characteristics

The cohort consisted of mostly middle-aged patients who had predominantly stage IIIB and IV ACC-SMAO located in the trachea (n=5) or main bronchus (n=3). All patients were assessed for injection and have received at least 4 injections. At baseline, mean airway tumor cross-sectional area was 153.3 mm^2 (n=8), and the mean airway obstruction rate was 86.1% (n=8) (*Table 1*). Two patients without CT assessment at day 30 post-treatment were not included in efficacy analysis. At the investigators' discretion, two patients (No. 7 and 8) had pre-treatment stent insertion for alleviating airway obstruction. The stents were removed after PTS treatment. No other concomitant treatment for relieving airway obstruction was performed for other patients.

Primary endpoints

Two patients without CT assessment at 30 days post-treatment were excluded from the efficacy analysis. According to the RECIST criteria, the airway ORR reached 100% [33.3% complete remission (CR) and 66.7% partial remission (PR)]. PTS treatment (mean: 17.8 mL; range, 8.2–40.0 mL) reduced the airway tumor size from 158.2 to 22.7 mm^2 and the average airway obstruction rate decreased from 83.1% to 14.4% (n=6).

Corresponding results were obtained by bronchoscopy to further demonstrate the anti-tumor effects of PTS (*Table S1*). At day 30, PTS treatment significantly reduced

the mean airway tumor area from 116.2 to 13.09 mm^2, and decreased the mean airway obstruction rate from 85.8% to 10.8% (n=6). The typical changes in tumor sizes during endoscopic examination are shown in *Figure 2*.

Secondary endpoints

No patient succumbed at one year after PTS treatment, whereas at 5 years two patients (25.0%) succumbed, four patients (50.0%) were still alive, and 2 patients (25.0%) were lost to follow-up (follow-up duration: 1.39 and 4.95 years, respectively). Therefore, the 5-year overall survival rate was 50.0%. The median survival duration was 4.98 years (range, 1.39–5.00 years) (*Figure S1*). Four patients (50.0%) were deemed to have stable disease.

Compared with BDI score, the TDI score increased significantly at 30 days after treatment (pre-treatment: 3.60±2.88; post-treatment: 9.00±1.87; mean difference: 5.40; 95% CI, 0.31–10.49; P<0.05). There was a progressive increase among the three patients (subjects No. 1, 2, and 4) who attended the 1 year follow-up assessment.

At follow-up, four patients had undergone spirometry, therefore spirometric data were only available in four patients in total. There was a non-significant increase in FEV_1 (from 1.18±0.71 liters to 2.60±1.51 liters, mean difference: 1.42 liters; 95% CI, −1.87 to 4.71 liters; P=0.264) and FEV_1/FVC (from 54.7±21.4 to 84.1±10.2, mean difference: 29.3; 95% CI, −8.5 to 67.1; P=0.09) in three out of four patients, although the trend was not statistically significant due to the limited number of patients included for analysis.

Adverse events

Adverse events (AEs) were reported in 75% (n=6) of patients, of whom 33.3% (n=2) and 66.7% (n=4) were rated as mild and moderate, respectively. No SAE was reported. The only one possible drug-related AE reported was tachypnea (12.5%, n=1), which was a reversible, mild and respiratory system related Grade 1 AE according to CTCAE (Common Terminology Criteria for Adverse Events) definition.

The most common AEs were injection-site hemorrhage (25%, n=2) and fever (25%, n=2) according to the Preferred Terms classification. Both AEs belonged to the general disorders and injection-site events (50%, n=4) according to the Systemic Organ Classification. Other AEs included cough (25%, n=2), tachypnea (12.5%, n=1), hemoptysis (12.5%,

Table 1 Baseline characteristics and treatment responses in patients with ACC-SMAO

Variables	Patient No.							
	1	2	3	4	5	6	7	8
Baseline characteristics								
Age (years)	84	60	35	52	40	58	28	40
Gender	Male	Male	Female	Female	Male	Female	Male	Female
Tumor location	Left main bronchus	Lower trachea	Left main bronchus	Upper trachea	Right main bronchus	Mid portion of trachea	Lower trachea	Mid portion of trachea
TNM staging	T4N2MX	T4NXM1	T4N3M1	T4N0M0	T3N0M1	T4N0MX	T4N0MX	T4N0MX
Pre-treatment CT assessment								
Date of pre-treatment assessment	Oct 22th, 2009	Jan 28th, 2010	Jan 17th, 2011	May 10th, 2010	Jan 14th, 2011	Nov 19th, 2010	Dec 26th, 2010	Jan 6th, 2011
Airway tumor cross-sectional area (mm^2)	126	158	30	133	189	247	133	210
Airway obstruction (%)	100	53.6	100	84.2	100	90.1	71.5	89.4

Table 1 (*continued*)

Table 1 (*continued*)

Variables	Patient No.							
	1	2	3	4	5	6	7	8
Post-treatment CT-assessment at day 30								
Date of post-treatment assessment	Jan 6th, 2010	Mar 16th, 2010	ND	Jun 29th, 2010	Mar 22th, 2011	ND	Feb 14th, 2011	Mar 11th, 2011
Airway tumor cross-sectional area (mm^2)	0	41	ND	23	0	ND	19	53
Airway tumor alleviation rate (%)	100.0	74.1	ND	82.7	100.0	ND	85.7	74.8
Airway objective response rate (RECIST criteria)	CR	PR	ND	PR	CR	ND	PR	PR
Percentage of airway obstruction	0	16.9	ND	24.0	0	ND	9.1	36.6
% reduction of airway obstruction	100	36.7	ND	60.2	100	ND	62.4	52.8
Final follow-up and treatment modality								
Date of the last follow-up	Aug 31st, 2016	Mar 28th, 2016	Mar 26th, 2016	Sep 30th, 2011	Dec 29th, 2015	May 16th, 2016	May 25th, 2016	Mar 31st, 2015
Total injection volume of PTS (mL)*	10.64	8.93	13.20	8.20	40.00	22.50	19.00	19.75
Survival status	Alive	Died	Alive	NA	NA	Died	Alive	Died
Duration of survival (years)**	>5.00	4.57	>5.00	1.39	4.95	>5.00	>5.00	4.23
Local recurrence of tumor	Yes (2016)	NA	NA	NA	NA	Yes (2015)	Yes	NA
Endoscopic treatment procedures (year of administration)	PTS injection (2009); Chinese herbs (2010–2013); argon plasma coagulation (2016)	PTS injection (2010)	PTS injection (2011)	PTS injection (2010)	PTS injection (2011)	PTS injection (2010); stent placing (2010); electrocautery (2015)	PTS injection (2010); argon plasma coagulation (2011); argon plasma coagulation plus electrocautery (2014); argon plasma coagulation (2014); particle beam radiotherapy (2014–2016)	PTS injection (2011); radiotherapy (2011)

*, the total injection volume of PTS referred to the volume of PTS being cumulatively given during the 1-year study period; **, the duration of survival was calculated as: (I) the date when the patients (who survived) entered the trial to the date of the last follow-up; (II) the date when the patients who were lost to follow-up, or to the date of death; ACC-SMAO, adenoid cystic carcinoma complicating with severe malignant airway obstruction; NA, not available; ND, not done; CR, complete remission; PR, partial remission; CT, computed tomography.

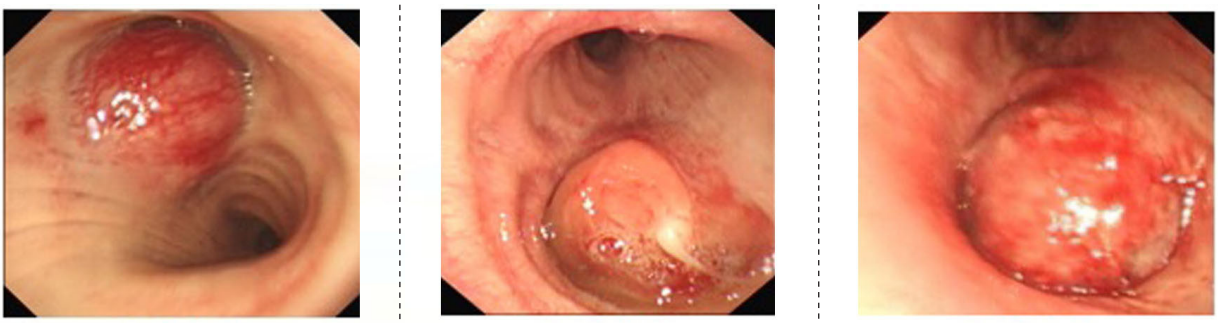

2009-10-30
Screening period
The 1st dosing (PTS 1 mL)
The tumor with sufficient blood supply competely occluded the left main bronchus.

2009-11-02
The 2nd dosing (PST 2 mL)
The tumor was partially necrotic with a smooth surface.

2009-11-04
The 3rd dosing (PST 2 mL)
The tumor became necrotic with reduced sizes. PST was injected following removal of the necrotic debris.

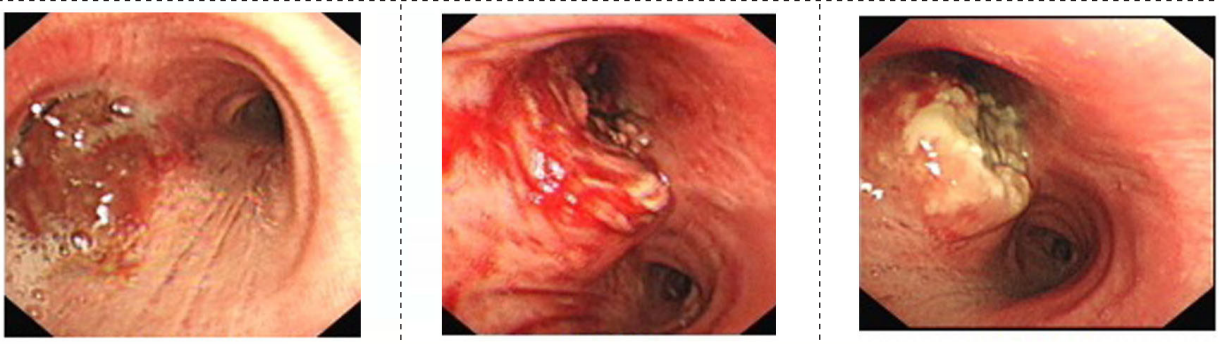

2009-11-09
The 4th dosing (PTS 2 mL)
The necrotic debris on the tumor surface was removed before further dosing.

2009-11-11
The 5th dosing (PTS 2.5 mL)
The reduced tumor size enabled the passage of the bronchoscope into left main bronchus. The debris was removed before PTS dosing.

2009-11-16
The 6th dosing (PTS 2.5 mL)
The tumor size was further decreased. The necrotic debris was removed before PTS injection.

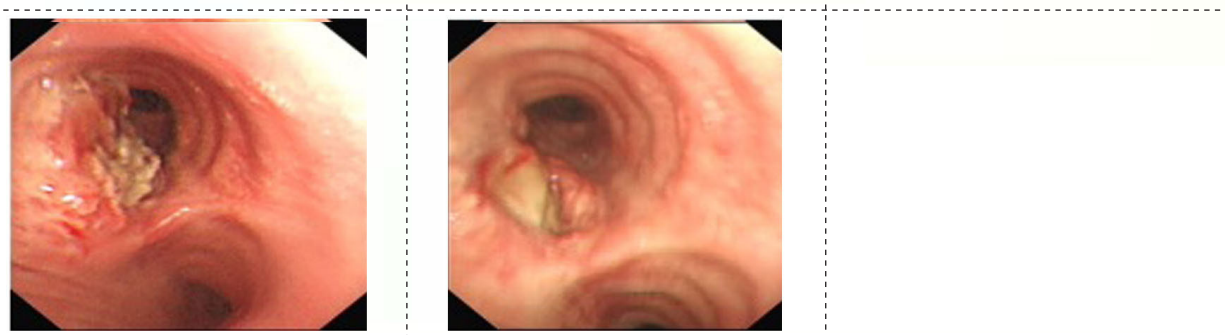

2009-11-27
Withdraw visit
The decrease in tumor size was ~80%, with an airway obstruction rate at 18.1%.

2010-01-05
30-day post-treatment follow-up
The tumor was virtually diminished and covered with necrotic debris.
The airway obstruction rate was 6.9%.

Figure 2 Pre-and post-treatment airway obstruction of a 77-year-old male patient (Subject 1) with TACC-SMO at the left main bronchus by bronchoscopy. On Oct 30, 2009 (pre-treatment), the tumor area within the airway, as assessed by bronchoscopy, was 12.0 mm × 10.1 mm. On Nov 27, 2009 (post-treatment), the tumor area within the airway, as assessed by bronchoscopy, was 9.0 mm × 2.4 mm. On Jan 05, 2010 (30 days post-treatment), the tumor area within the airway, as assessed by bronchoscopy, was 7.0 mm × 1.7 mm.

n=1), loss of appetite (12.5%, n=1), and abdominal pain and vomiting (12.5%, n=1). See *Table S2* for further details.

No significant abnormalities (including bone marrow inhibition) in laboratory tests were noted (data not shown).

Discussion

Our study demonstrated that PTS rapidly debulked ACC-SMAO, resulting in a considerable improvement of 5-year survival rate.

Aside from the longer survival in patients with ACC-SMAO, we also compared the response rate of ACC-SMAO and other patients with non-small cell lung cancer in our previously published study (5). The airway ORR of patients with ACC-SMAO and other patients with lung cancer was 75.0% and 50.8% (chi-square: 1.66, P=0.20), respectively. Despite a significant difference which might be due to our small sample sizes, there was a trend towards greater airway ORR which is reflective of the therapeutic responses between ACC-SMAO and other pathological subtypes of non-small cell lung cancer.

ACC differs from other pathological subtypes of lung cancer because the diagnosis of ACC could be frequently delayed due to the normal or near-normal manifestations on chest radiography or CT (7). However, upon diagnosis, the development of severe dyspnea due to large tumor sizes could have rendered the patients unsuitable for surgical removal. Further complicating the clinical management of ACC is the limited response to chemotherapy and radiotherapy (8). Moreover, ACC-SMAO remains challenging for respiratory physicians due to rapid recurrence that frequently warrants bronchoscopic interventions (9). Although silicone stent placement effectively ameliorated airway obstruction, they cannot be removed from airways (10). An advantage of PTS administration might be the minimal need for foreign body placement. Moreover, despite that patients with ACC reportedly had good long-term outcomes (e.g., up to 10 years) (9,11), few or none of them had developed SMAO on presentation. Our findings were unique in that we have demonstrated the efficacy of PTS injection in the most severe form of pulmonary ACC. The patients enrolled in our study had notably longer survival than those of the general patients with stage IV NSCLC, possibly because of their slow growth of ACC-SMAO. The timely alleviation of major airway obstruction with PTS could be clinically appealing when virtually no other options were available. Because of the safety and effectiveness for alleviating large-airway obstruction, PTS intratumoral injection might be a novel, effective therapy for inoperable ACC-SMAO, particularly in developing countries where sophisticated medical facilities (e.g., electrocautery) are lacking.

Nevertheless, our study was limited by the finite post-treatment assessments of tumor sizes and dyspnea index that were conducted at day 30 only. We cannot address how PTS injection led to improved outcomes using other clinically relevant parameters (e.g., lung function). Therefore, larger trials which incorporate more comprehensive assessments to confirm the efficacy and safety of PTS in patients with ACC-SMAO are warranted.

Acknowledgements

We truly appreciate the dedication of Professor Q Li (Shanghai General Hospital, Shanghai, China) for recruiting some of the patients. We highly appreciate the insightful suggestions from Drs. W Huang, E Tu, M Hsiao, P Hsiao, M Lin, J Chang, and B Wang (Gongwin BioPharm Co., Ltd., Taiwan; PTS International Inc., USA). We also thank Guangdong Dari Chemicals Inc. (Guangzhou, China) for providing study medications, and the patients who took consent in participation in our study.

Funding: Guangdong Province Universities and Colleges Pearl River Scholar Funded Scheme 2017 (to Dr. Guan); Changjiang Scholars and Innovative Research Team in University ITR0961, The National Key Technology R&D Program of the 12th National 5-year Development Plan 2012BAI05B01 and National Key Scientific & Technology Support Program: Collaborative innovation of Clinical Research for chronic obstructive pulmonary disease and lung cancer No. 2013BAI09B09 (to Prof. Zhong).

Footnote

Conflicts of Interest: The authors have no conflicts of interest to declare.

Ethical Statement: Protocol approval was obtained from Ethics Committee of participating sites and China Food and Drug Administration [No.: 2009L03443; Medical Ethics Year 2009 (the 12th) and Medical Ethics Year 2016 (the 33rd) for follow-up study]. Informed consent forms were signed before enrollment.

References

1. Maziak DE, Todd TR, Keshavjee SH, et al. Adenoid cystic carcinoma of the airway: thirty-two-year experience. J Thorac Cardiovasc Surg 1996;112:1522-31.
2. Kokturk N, Demircan S, Kurul C, et al. Tracheal adenoid cystic carcinoma masquerading asthma: a case report. BMC Pulm Med 2004;4:10.
3. Gaissert HA, Grillo HC, Shadmehr MB, et al. Long-term survival after resection of primary adenoid cystic and squamous cell carcinoma of the trachea and carina. Ann Thorac Surg 2004;78:1889-96.
4. Gao Y, Gao Y, Guan W, et al. Antitumor effect of para-toluenesulfonamide against lung cancer xenograft in a mouse model. J Thorac Dis 2013;5:472-83.
5. Li SY, Li Q, Guan WJ, et al. Effects of para-toluenesulfonamide intratumoral injection on non-small cell lung carcinoma with severe central airway obstruction: A multi-center, non-randomized, single-arm, open-label trial. Lung Cancer 2016;98:43-50.
6. Osborn DA. Morphology and the natural history of cribriform adenocarcinoma (adenoid cystic carcinoma). J Clin Pathol 1977;30:195-205.
7. Velez Jo ET, Morehead RS. Hemoptysis and dyspnea in a 67-year-old man with a normal chest radiograph. Chest 1999;116:803-7.
8. Soldà C, Pastorelli D, Bridda A. Tracheal Cacner: A comprehensive Review. Ann Otolaryngol Rhinol 2015;3:1079.
9. Lee JH, Jung EJ, Jeon K, et al. Treatment outcomes of patients with adenoid cystic carcinoma of the airway. Lung Cancer 2011;72:244-9.
10. Eom JS, Kim B, Kim H, et al. Fibrotic airway stenosis following radiotherapy in patients with adenoid cystic carcinoma. Respirology 2014;19:914-20.
11. Shimizu J, Oda M, Matsumoto I, et al. Clinicopathological study of surgically treated cases of tracheobronchial adenoid cystic carcinoma. Gen Thorac Cardiovasc Surg 2010;58:82-6.

Cite this article as: Guan WJ, Li SY, Zhong NS. Effects of para-toluenesulfonamide intratumoral injection on pulmonary adenoid cystic carcinoma complicating with severe central airway obstruction: a 5-year follow-up study. J Thorac Dis 2018;10(4):2448-2455. doi: 10.21037/jtd.2018.03.70

Table S1 Characteristics of ACC-SMAO patients

Variables	Subject 1	Subject 2	Subject 3	Subject 4	Subject 5	Subject 6	Subject 7	Subject 8
Baseline characteristics								
Age at enrollment (years)	84	60	35	52	40	58	28	40
Gender	Male	Male	Female	Female	Male	Female	Male	Female
Tumor location	Left main bronchus	Lower trachea	Left main bronchus	Upper trachea	Right main bronchus	Mid portion of trachea	Lower trachea	Mid portion of trachea
Overall tumor size (mm)	39.8×27.9×37.0	40.0×36.4×70.7	35.1×24.1×57.5	50.3×29.2×35.4	34.5×21.0×26.6	15.1×17.8×24.6	28.1×24.2×41.7	24.0×21.0×64.2
TNM staging	T4N2MX	T4NXM1	T4N3M1	T4N0M0	T3N0M1	T4N0MX	T4N0MX	T4N0MX
Pre-treatment assessment								
Date of bronchoscopic pre-treatment assessment	Oct 30th, 2009	Jan 29th, 2010	Jan 13th, 2011	May 11th, 2010	Jan 17th, 2011	Nov 19th, 2010	Dec 28th, 2010	Jan 7th, 2011
Airway tumor cross-sectional area (mm^2)	102.3	49.3	69.1	99.9	105.4	105.0	248.6	91.8
Airway obstruction rate (%)	100.0%	62.0%	100.0%	84.3%	100.0%	86.0%	84.5%	84.2%
BDI	6	7	7	2	0	4	3	7
FEV_1	ND	1.74	ND	1.84	ND	ND	0.64	0.48
FEV_1/FVC (%)	ND	80.9	ND	48.0	ND	ND	60.0	30.0
30 days post-treatment assessment								
Date of bronchoscopy post-treatment assessment	Jan 5th, 2010	Mar 15th, 2010	ND	Jun 29th, 2010	Mar 22th, 2011	ND	Feb 16th, 2011	Mar 14th, 2011
Airway tumor cross-sectional area (mm^2)	8.0	2.5	ND	34.6	16.3	ND	9.1	8.2
Airway tumor alleviation rate (%)	92.2	94.9	ND	65.4	84.6	ND	96.3	91.1
Airway obstruction (%)	6.9	3.0	ND	29.0	15.1	ND	3.1	7.6
Alleviation of airway obstruction rate	93.1	59	ND	55.3	84.9	ND	81.4	76.6
TDI	7	8	ND	9	9	ND	12	ND
FEV_1	ND	1.18	ND	2.01	ND	ND	4.71	2.48
FEV_1/FVC	ND	77.3	ND	78.0	ND	ND	99.0	82.0
1 year post-treatment assessment								
Date of post-treatment assessment	Dec 7th, 2010	Feb 19th, 2010	ND	May 13th, 2011	ND	ND	ND	ND
TDI	9	12	ND	10	ND	ND	ND	ND

BDI, Baseline Dyspnea Index; TDI, Transitional Dyspnea Index; FEV_1, forced expiratory volume in 1 second; FVC, forced vital capacity; ND, not done.

Table S2 Summary of adverse events

Domain abbreviation	Unique subject identifier	Subject identifier	Visit sequence number	Page identifier	Line identifier	Sequence number	Adverse events	Date occurred	Date ended	Severity	Treatment	Titration of the dose of PTS	Relevance to PTS injection	Prognosis
AE	01001	01001	7	62	1	1	Cough, tachypnea	31-Oct-09	2-Nov-09	Mild	Oxygen therapy, mucolytics, bronchospasmolytics	None	Possibly relevant	Alleviated without sequelae
AE	01001	01001	7	62	2	2	tachypnea	14-Nov-09	15-Nov-09	Mild	Reducing the volume of intravenous fluids	None	Irrelevant	Alleviated without sequelae
AE	01001	01001	7	62	3	3	fever	2-Nov-09	2-Nov-09	Moderate	symptomatic therapy (details unknown)	None	Irrelevant	Alleviated without sequelae
AE	01005	01005	7	62	1	1	hemoptysis (minor)	30-Jan-10	30-Jan-10	Mild	None	None	Irrelevant	Alleviated without sequelae
AE	01005	01005	7	62	2	2	hemoptysis (minor)	2-Feb-10	2-Feb-10	Mild	Compound glycyrrhizae	None	Irrelevant	Alleviated without sequelae
AE	01005	01005	7	62	3	3	hemoptysis (minor)	4-Feb-10	4-Feb-10	Mild	Compound glycyrrhizae	None	Irrelevant	Alleviated without sequelae
AE	01005	01005	7	62	4	4	cough and sputum production	6-Feb-10	6-Feb-10	Mild	Compound glycyrrhizae	None	Possibly irrelevant	Alleviated without sequelae
AE	01019	01019	7	62	1	1	abdominal pain and vomiting	24-Jan-11	25-Jan-11	Moderate	Montmorillonite powder, berberine oral administration	None	Possibly irrelevant	Alleviated without sequelae
AE	01019	01019	7	62	2	2	loss of appetite	21-Jan-11	21-Jan-11	Mild	None	None	Irrelevant	Alleviated without sequelae
AE	17008	17008	7	62	1	1	injection-site hemorrhage	24-Nov-10	25-Nov-10	Mild	Coagulase 200 units	None	Irrelevant	Alleviated without sequelae
AE	17010	17010	7	62	1	1	injection-site hemorrhage	30-Dec-10	30-Dec-10	Mild	Coagulase intravenous injection	None	Possibly irrelevant	Alleviated without sequelae
AE	17011	17011	7	62	1	1	cough	14-Jan-11	14-Jan-11	Mild	Compound glycyrrhizae	None	Possibly irrelevant	Alleviated without sequelae
AE	17011	17011	7	62	2	2	fever	14-Jan-11	14-Jan-11	Mild	Sodium diclofenac oral administration	None	Possibly irrelevant	Alleviated without sequelae

PTS, para-toluenesulfonamide.

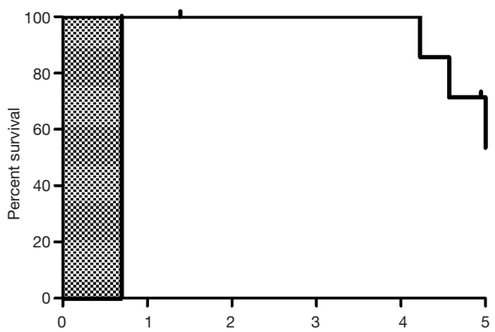

Figure S1 The 5-year overall survival in patients with ACC-SMAO. ACC-SMAO, adenoid cystic carcinoma-severe malignant airway obstruction.